Latvijas Osteoporozes un kaulu metabolo slimību asociācija

AMGEN

aslimnica
RĪGAS AUSTRUMU KLĪNISKĀ UNIVERSITĀTES SLIMNĪCA

World Osteoporosis Day October 20

RĪGAS STRADIŅA UNIVERSITĀTE

IOF International Osteoporosis Foundation

Osteoporotiskie lūzumi

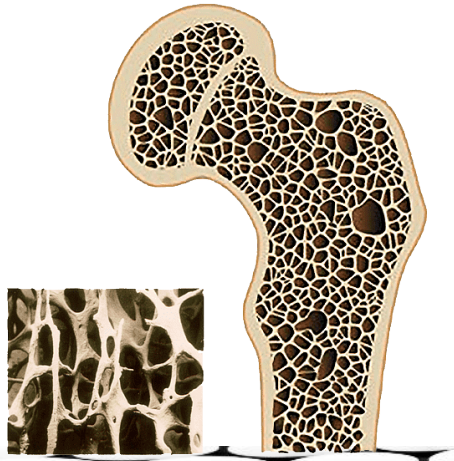

Valts Boginskis

Latvijas traumatologu un ortopēdu asociācijas valdes loceklis
Latvijas Universitāte
Ziemeļkurzemes reģionālā slimnīca

20.10.2023.

Klusais slepkava

40-50% sieviešu pēc 50 gadu vecuma
13-22% vīriešu pēc 50 gadu vecuma

50% būs atkārtots lūzums, kas eksponenciāli paaugstina atkārtota lūzuma risku.

Johnell O, Kanis J. Epidemiology of osteoporotic fractures. Osteoporos Int. 2005

CM, Ross PD, Landsman PB, et al. Patients with prior fractures have an increased risk of future fractures: a summary of the literature and statistical synthesis. J Bone Miner Res. 2000

Osteoporoze

Sistēmiska kaulu slimība kuru raksturo pazeminās kaulu minerālais blīvums un kaulaudu mikroarhitektoniskas izmaiņas, kā rezultātā paaugstinās kaulu trauslums un pie zemas enerģijas traumām attīstās kaula lūzums.

Būtībā hroniska slimība ar akūtām fāzēm vai simptomiem, kas izpaužas kā lūzumi.

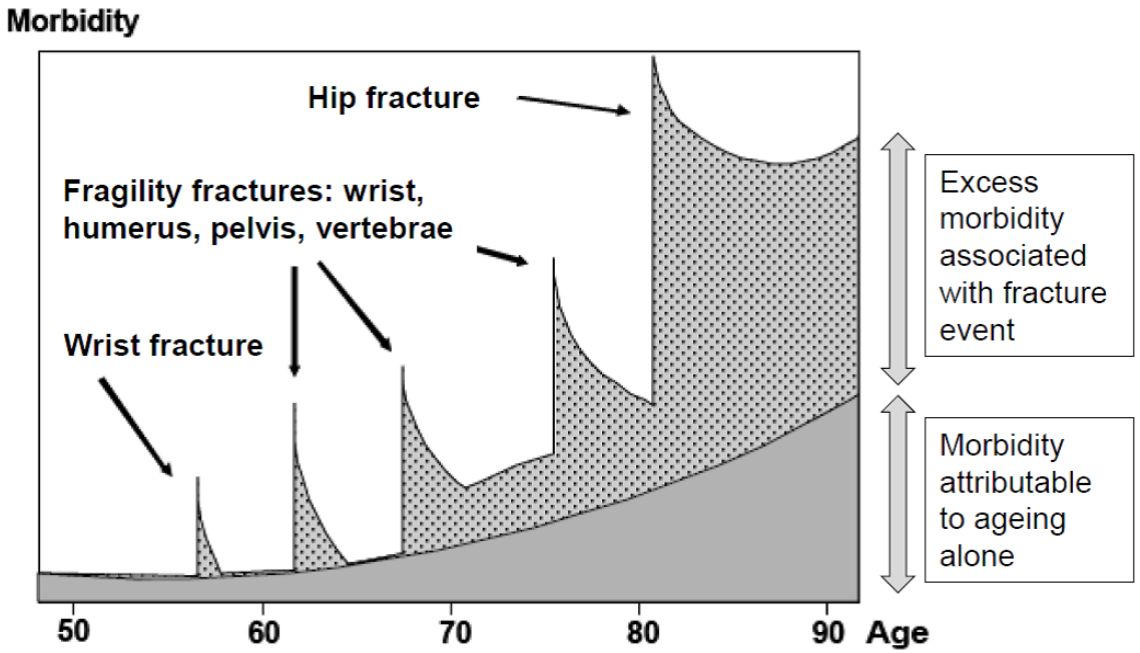

Kanis JA, Johnell O. The burden of osteoporosis. J Endocrinol Invest. 1999.

60–85% sieviešu ar osteoporotisku lūzumu gada laikā nav uzsākta terapija.

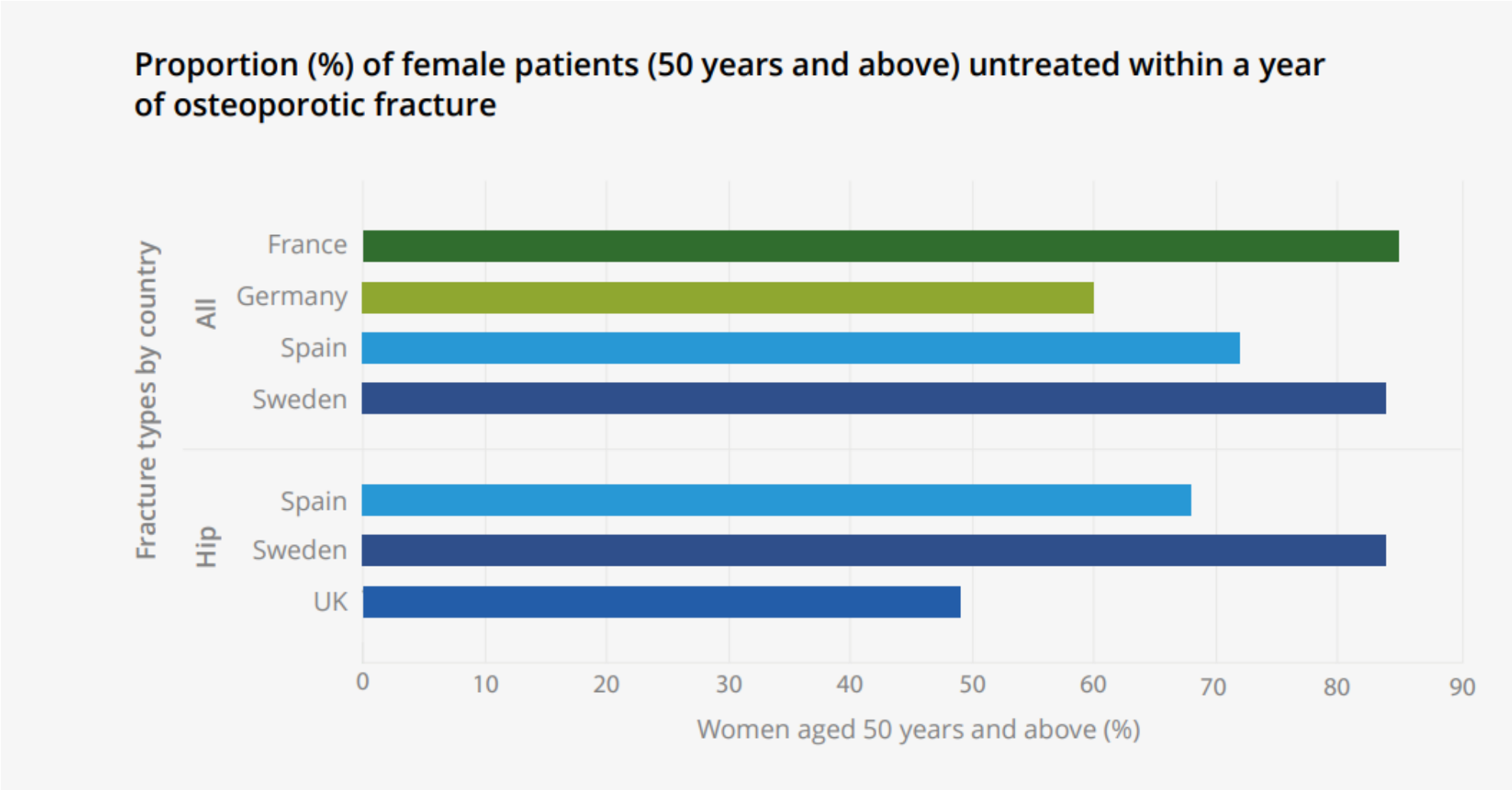

Traumatologa ortopēda rakstveida sniegtās rekomendācijas, pacientam izrakstoties

Kopā tikai 22 pacientiem jeb **2,5%** ar notikušu augšstilba kaula kakliņa lūzumu zemas energijas traumas rezultātā traumatologs ortopēds ir sniedzis rakstveida rekomendācijas par osteoporozes diagnostiku vai ārstēšanu tālākajā ambulatorās aprūpes etapā.

Osteoporotisks lūzums

WHO fragility fracture: “a fracture caused by an injury that would be insufficient to fracture normal bone; the result of reduced compressive and/or torsional strength of bone”.

Osteporotisks lūzums ir lūzums kurš veidojas nelielas traumas rezultātā, kā kritiens no stāvus pozīcijas vai mazāka augstuma.

ZIEMEĻKURZEMES REĢIONĀLĀ SLIMNĪCA

Osteoporotisks lūzums

24.7%

17.7%

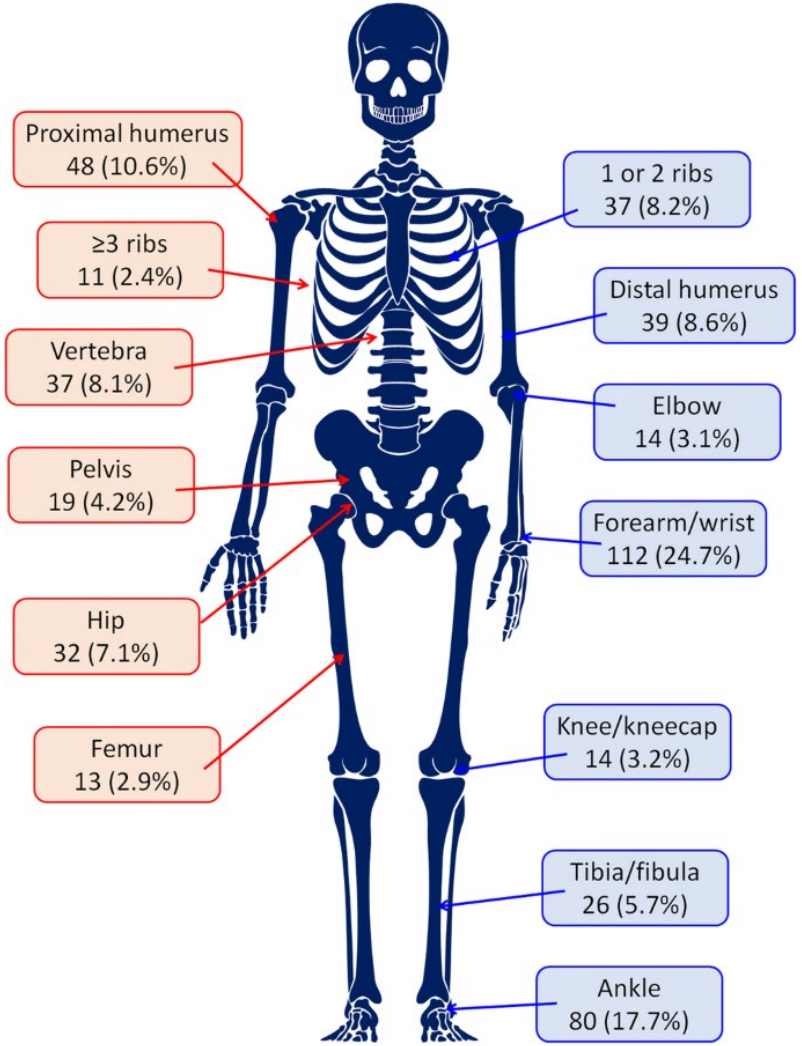

Cortet, B., Chauvin, P., Feron, JM. *et al.* Fragility fractures in France: epidemiology, characteristics and quality of life (the EPIFRACT study). *Arch Osteoporos* **15**, 46 (2020).

Osteoporozes ietekme uz kortikālo kaulu

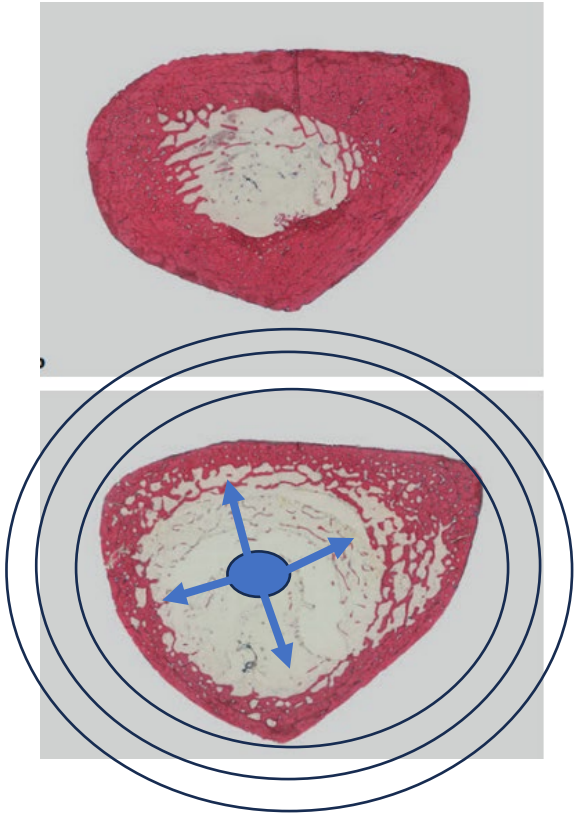

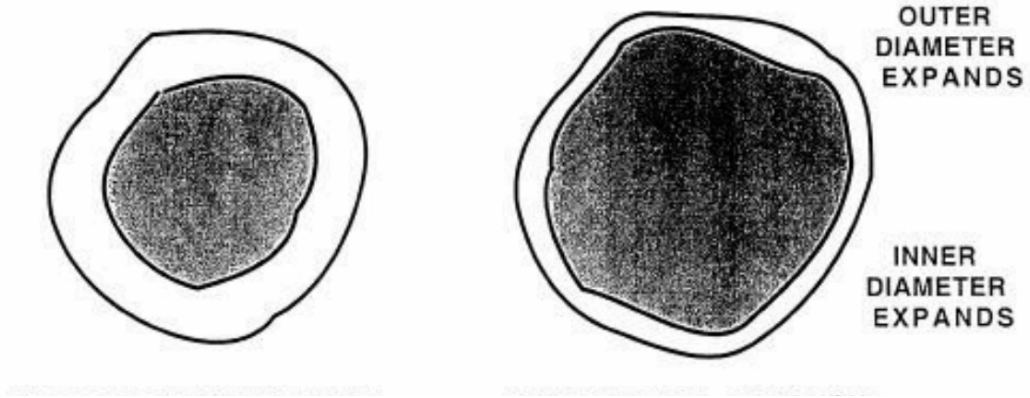

Kortikālā kaula lieces izturība = (ārējais kaula diametrs)^4 - (kaula kanāla diametrs)^4.

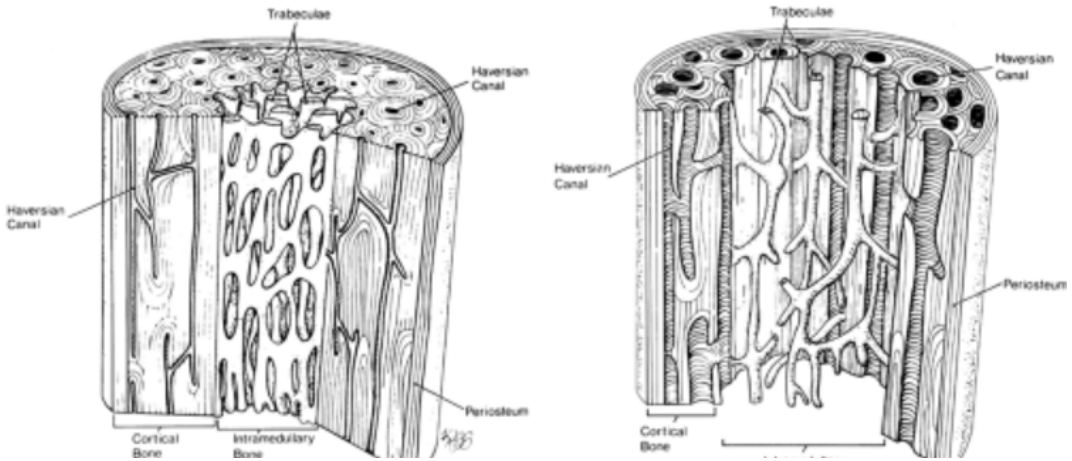

Images of histological sections courtesy of Beat Schmutz, Davos, Switzerland

ZIEMEĻKURZEMES REĢIONĀLĀ SLIMNĪCA

Osteoporozes ietekme uz spongiozo kaulu

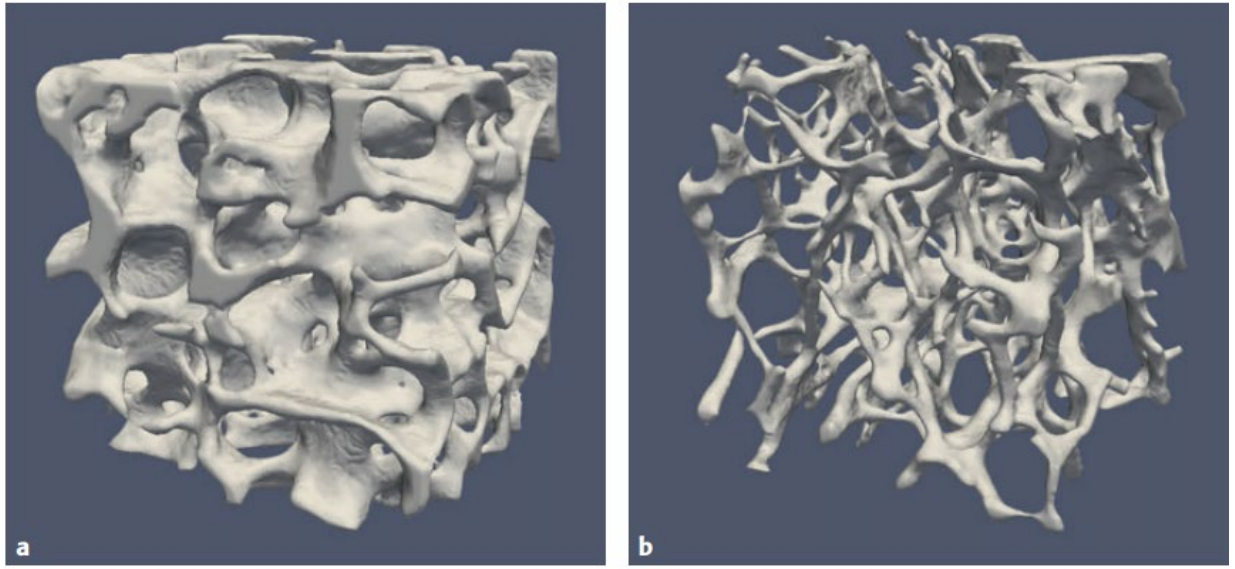

Fig 4.8-4a–b Age-related changes in trabecular bone quality. Besides drastic loss in bone mass, plate-like structures change into rod-like structures with aging as shown by these micro-computed tomographic images at age 35 (**a**) versus 73 (**b**) years. (Images by courtesy of Prof. Dr. Ralph Müller, Institute for Biomechanics at the ETH Zurich, Switzerland).

Mazinās

- trabēkulu biezums
- trabēkulu skaits
- trabēkulu savienujumu skaits

Izjaukts trabēkulu tīkls

Trabekulas maina savu anatomisko izskatu no plakanām uz cirkulārām.

Osteoporozes ietekme uz kaulu

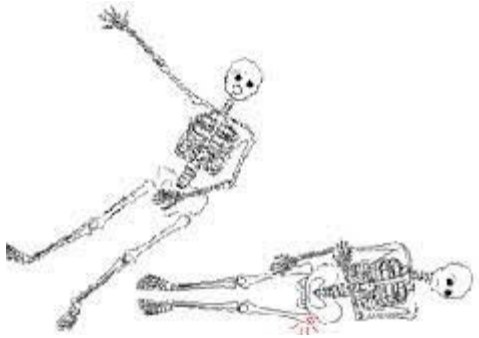



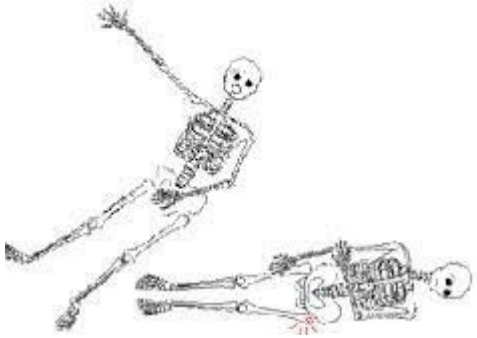

Osteoporotisku lūzumu ārstēšanas principi

- Kaula lūzuma anatomiska repozīcija – ass, rotācija, garums.
- Stabila fiksācija - **relatīva** vai absolūta stabilitāte.
- Saglabāt asins apgādi.
- Agrīna pacienta un ekstremitātes mobilizācija
- **Laiks līdz operācijai (24-48h)**
- **Uzmanīga apiešanās ar mīkstajiem audiem.**
- **Jāpielāgo fiksācija pie kaulu deformācijas.**
- **Izvēlētai fiksācijas metodei jāiztur pacienta pilna lūzuma zonas slogošana – endoprotezēšana – one shot surgery princips.**
- **Atkārtotu lūzumu risku mazināšana.**

Kā nodrošināt lūzuma stabilitāti, repozīciju, saglabājot fragmentu asinsapgādi.?

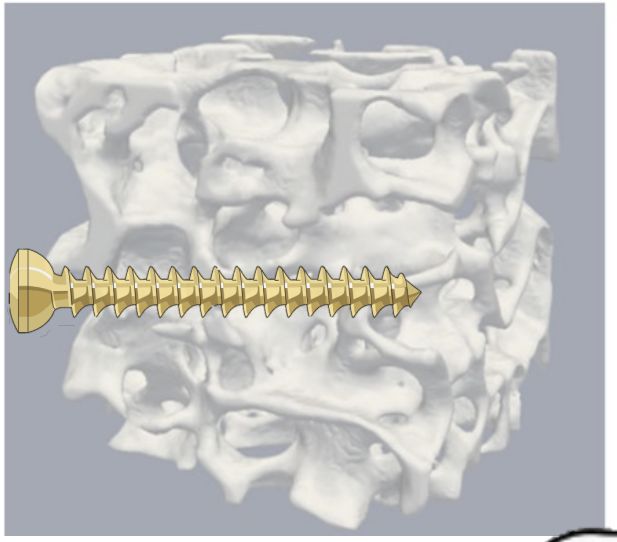

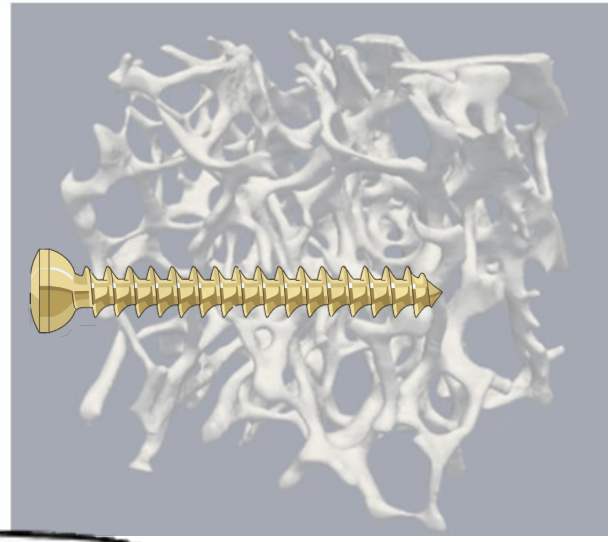

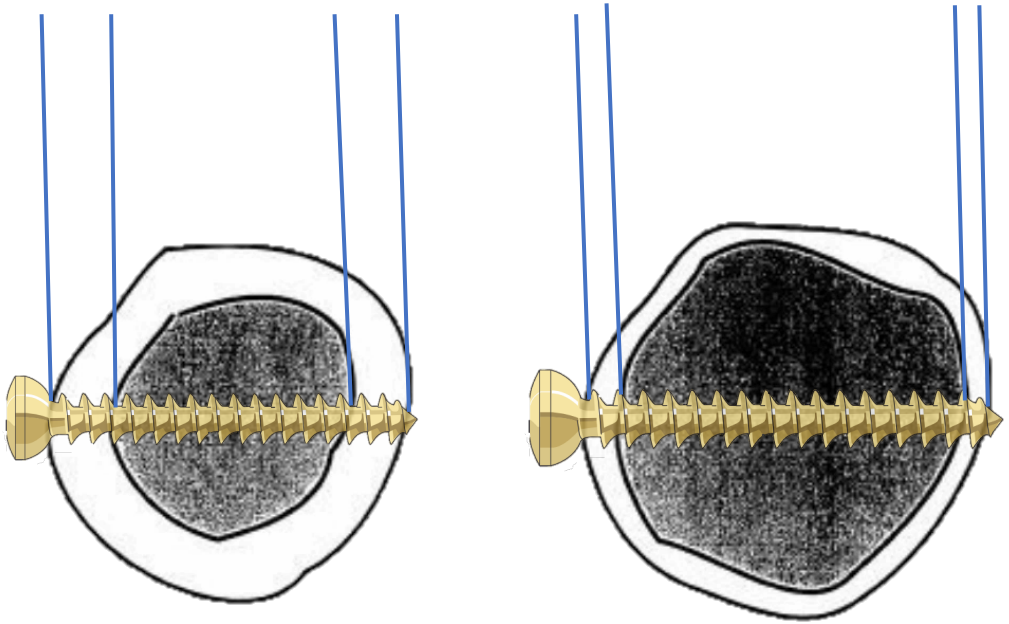

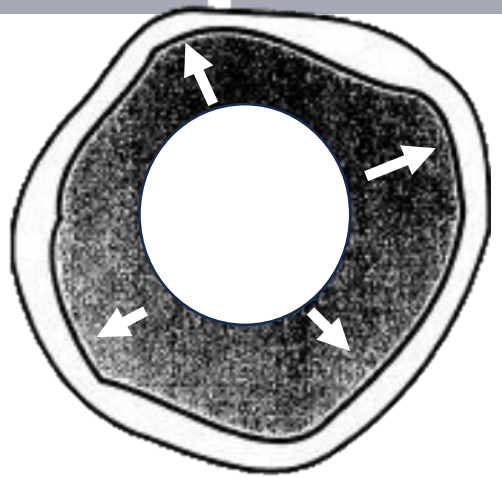



Kaula lūzuma anatomiska repozīcija izmantojot netiešas repozīcijas metodes.

- Trakscijas galds, vai asistents kā trakcijas veicējs
- Ārējās fiksācijas aparāts
- Distraktors
- Izmantot šanca skrūvi kā džoistiku.
- Citi rīki lai nodrošinātu repozīciju.

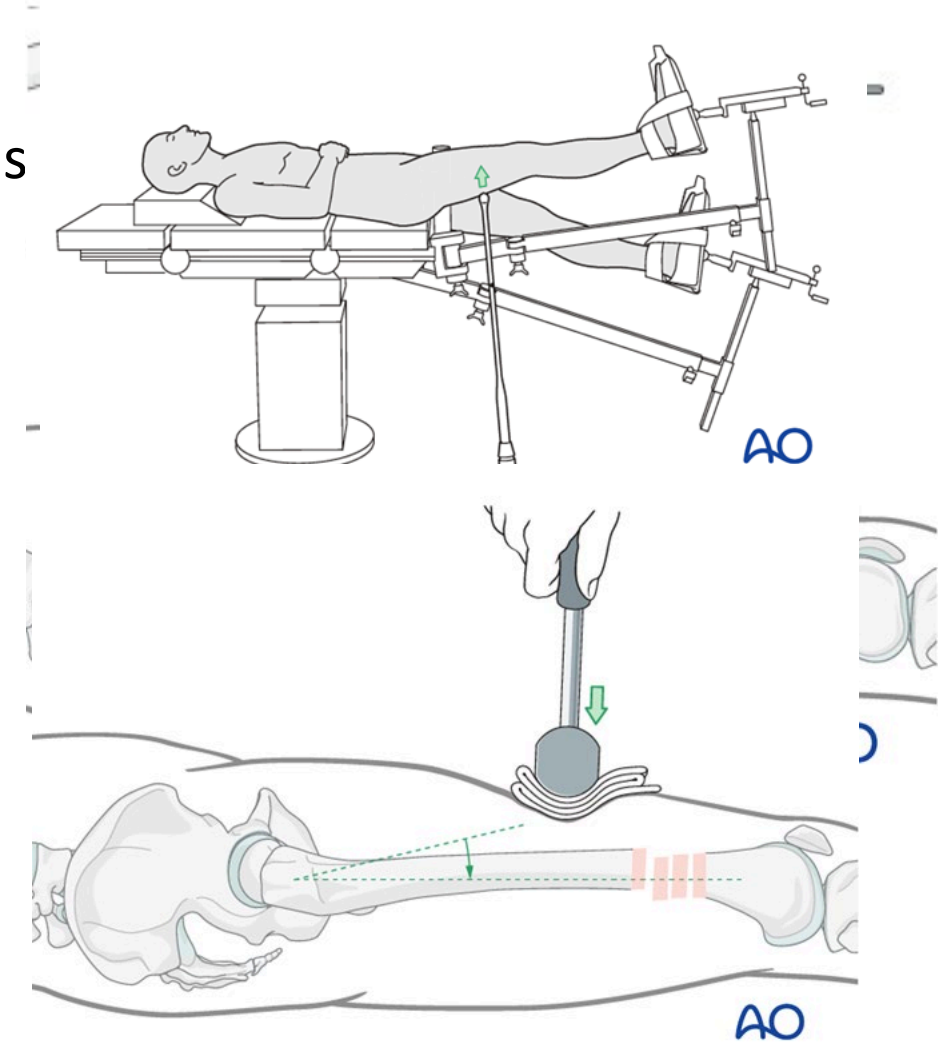

Kaula lūzuma tieša repozīcija

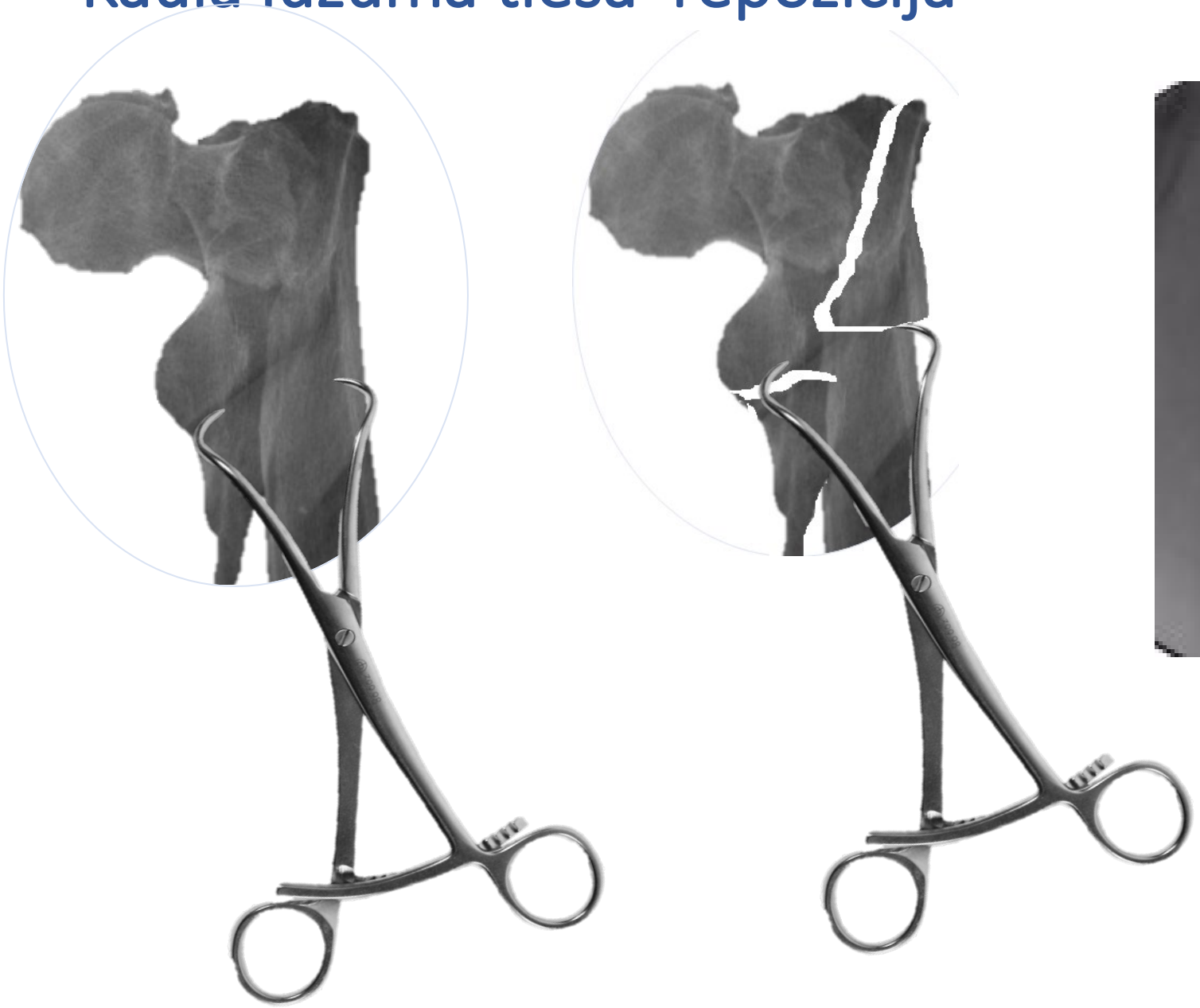

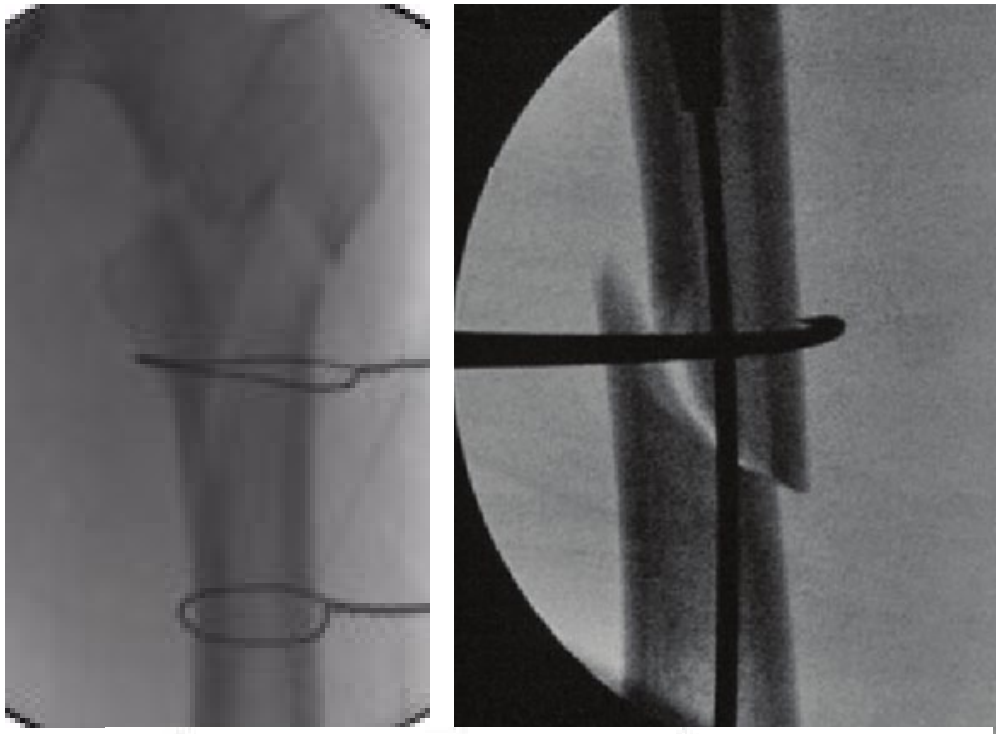

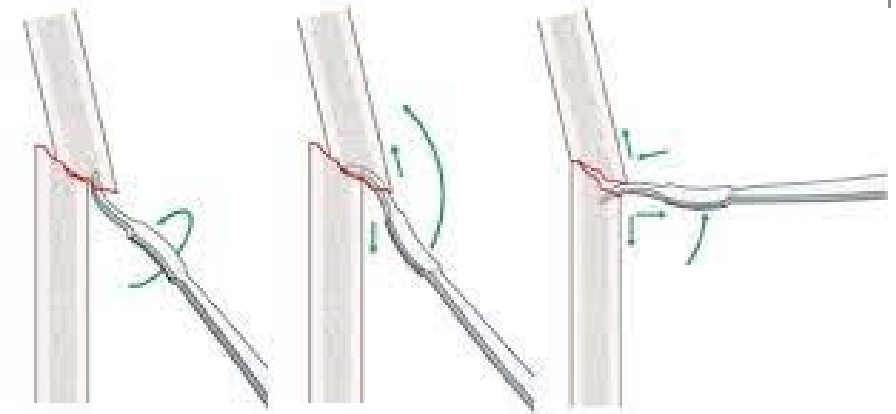

Stabila fiksācija – relatīva vai absolūta stabilitāte

- Ne artikulāriem lūzumiem labāk izmantot relatīvu stabilitāti lūzumu dzīšanā.
- Artikulārie lūzumiem nepieciešama perfekta anatomiska repozīcija.

72 g.v.
Paslidēja uz slapjas grīdas

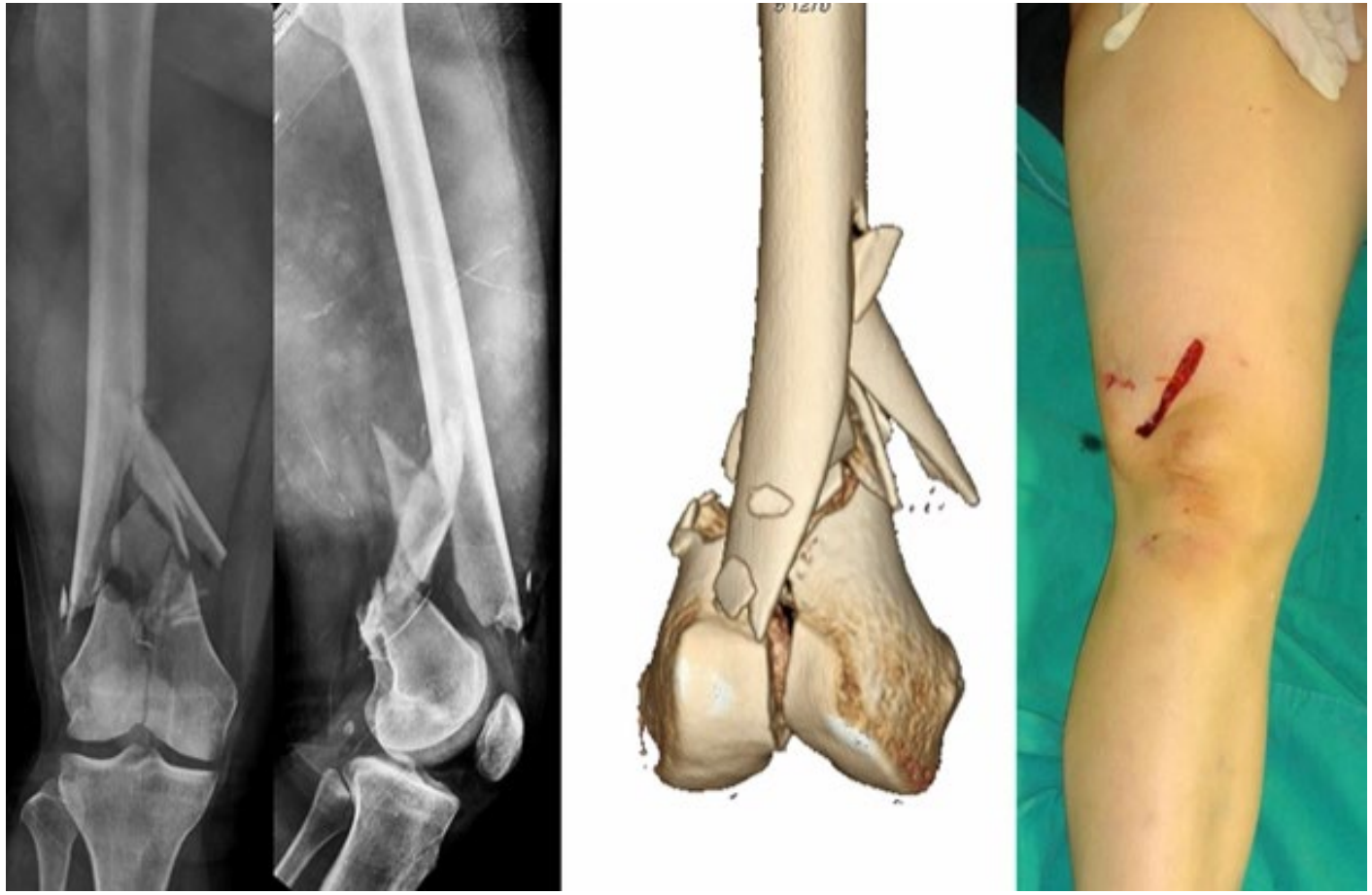

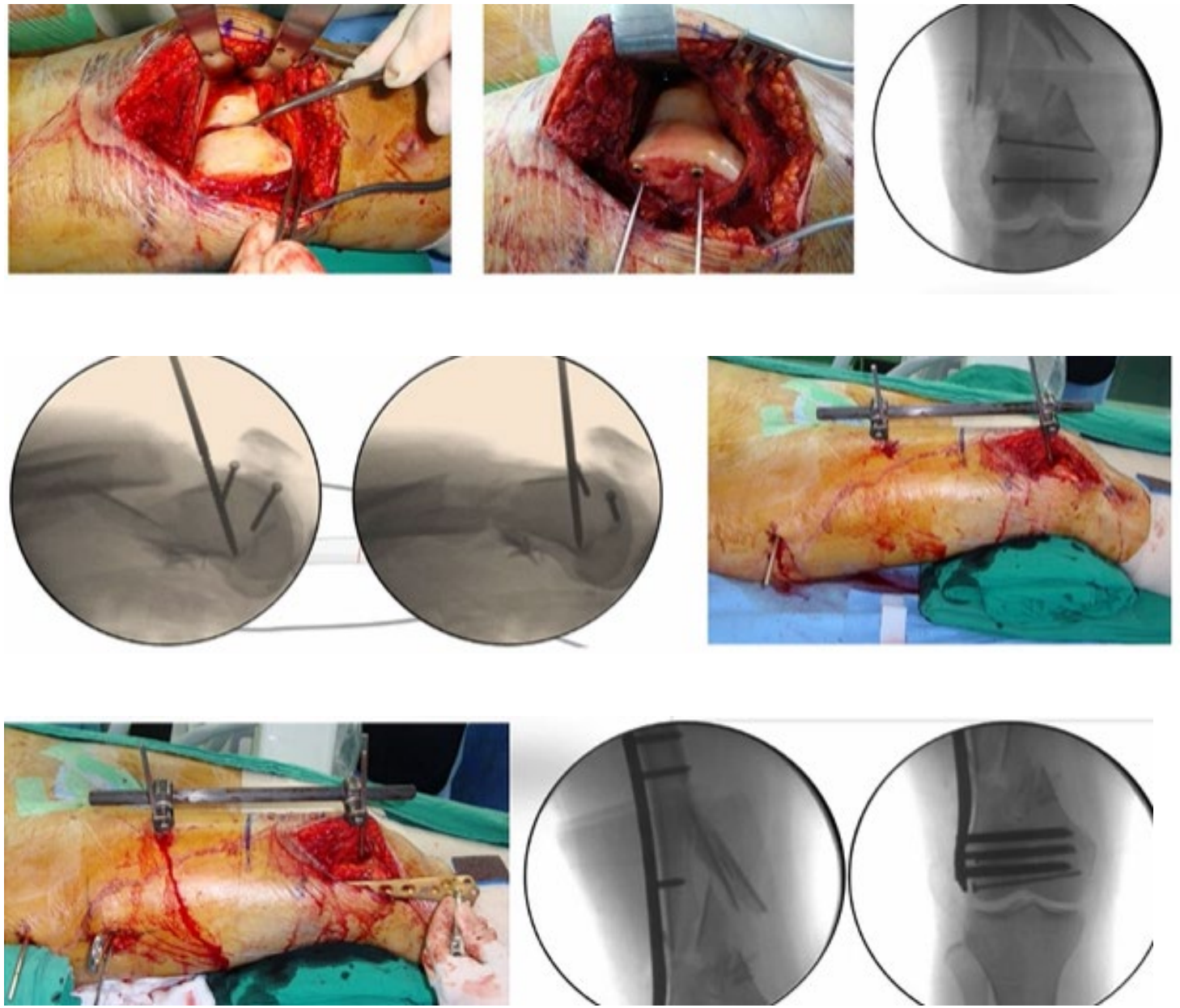

1 gads pēc traumas

Saglabāt lūzuma fragmentu asins apgādi

Netiešas lūzuma repozīcijas tehnikas
Minimāli invazīvas tehnikas

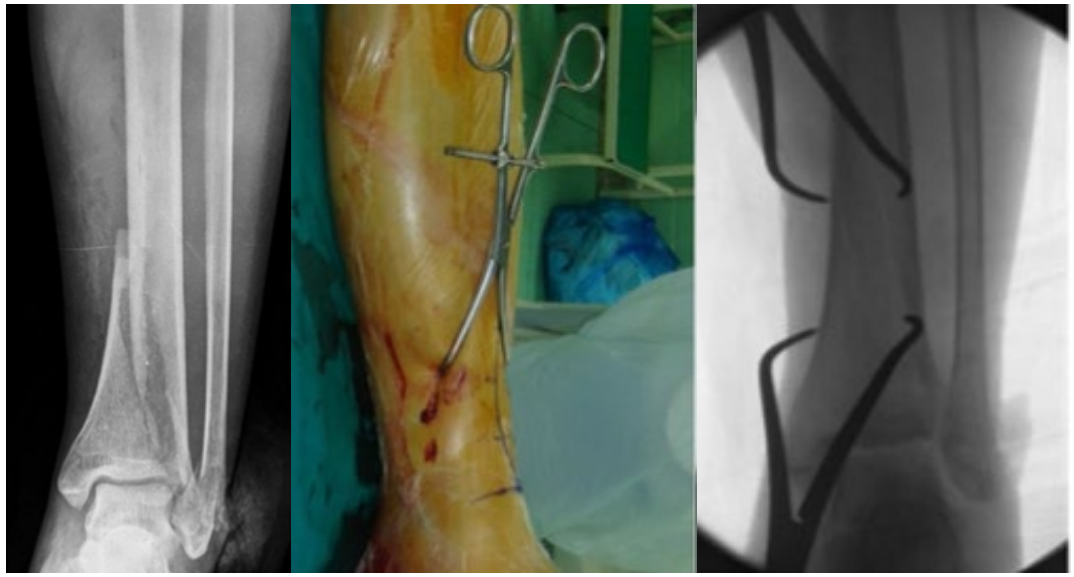

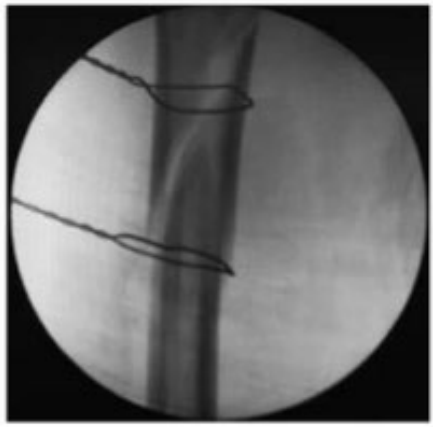

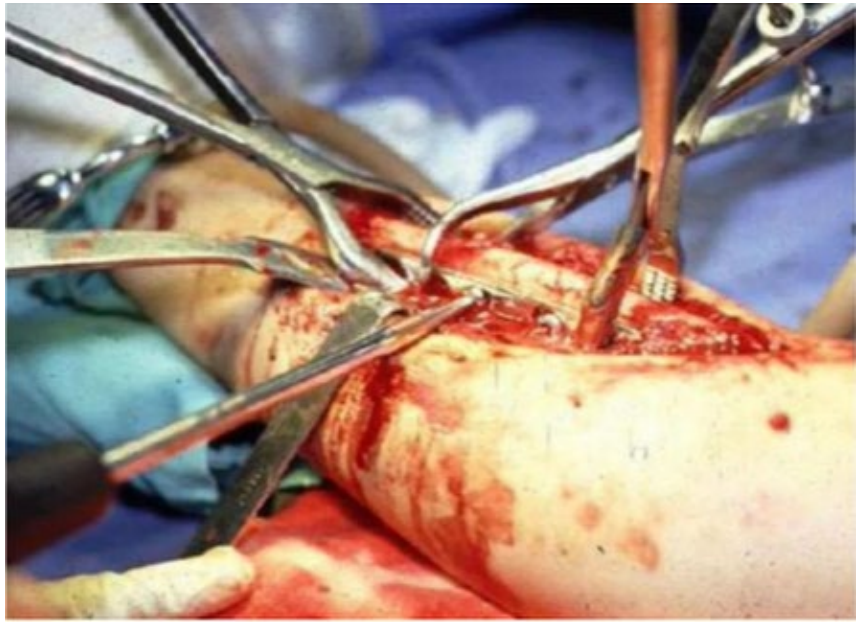

Agrīna pacienta un ekstremitātes mobilizācija

↓ pacientu mirstība
↓ pēcoperācijas delīrija veidošanās
↓ trombožu riski
↓ izgulējumu riski
↓ pneimonijas un UCI biežums
↓ muskuļu masas zudums
↓ kaulu masas zudums
↓ atkarība no apkārtējiem
↓ pēctraumatiska depresija
↓ aizcietējumu veidošanās
↓ slimnīcā pavadītais dienu skaits

↑ kustību apjoms locītavās
↑ lūzuma dzīšana
↑ tūskas mazināšanās
↑ brūču dzīšana
↑ funkcionālais stāvoklis

- Aprisunadi, Nursalam N, Mustikasari M, Ifadah E, Hapsari ED. Effect of Early Mobilization on Hip and Lower Extremity Postoperative: A Literature Review. SAGE Open Nurs. 2023 Apr
- Wall BT, Dirks ML, van Loon LJ. Skeletal muscle atrophy during short-term disuse: implications for age-related sarcopenia. Ageing Res Rev. 2013

Saudzīga apiešanas ar mīkstajiem audiem

- Ar gadiem āda zaudē savu elasticitāti un paliek plāna. Nepietiekama uztura rezultātā tauku slānis samazinās.
- Pie artēriju aterosklerozes, vēnu nepietiekamības raksturīgas ādas trofikas izmaiņas, tūskas, čūlas, brūču dzīšanas problēmas.
- Jāizvēlas mazinvazīvas ķirurģiskās metodes.

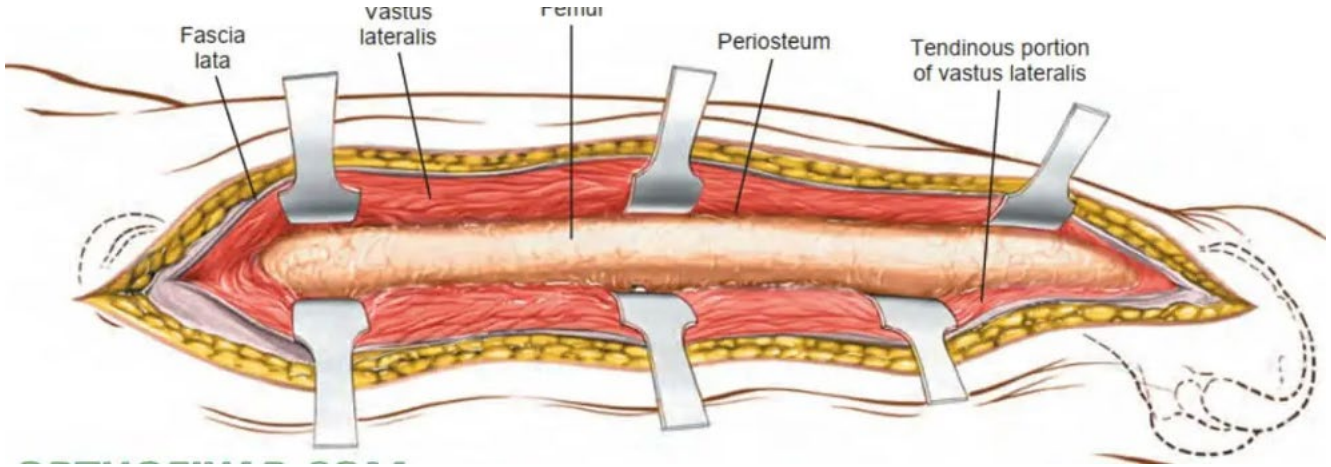
Fascia lata
Vastus lateralis
Periosteum
Tendinous portion of vastus lateralis

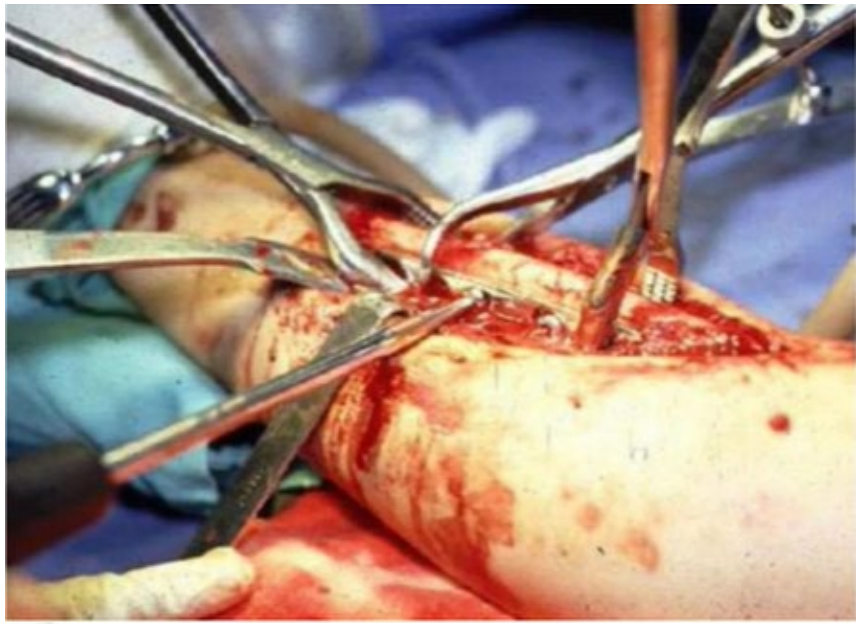

Augšstilba kaula gadījumā laiks līdz operācijai 24-48h

Lielākā daļa pētījumu iesaka operāciju veikt pirmo 24-48 stundu laikā, lai mazinātu mirstības rādītājus un perioperatīvo komplikāciju skaitu.

- Simunovic N, Devereaux PJ, Sprague S, Guyatt GH, Schemitsch E, Debeer J, Bhandari M. Effect of early surgery after hip fracture on mortality and complications: systematic review and meta-analysis. CMAJ. 2010 Oct 19
- ischer H, Maleitzke T, Eder C, Ahmad S, Stöckle U, Braun KF. Management of proximal femur fractures in the elderly: current concepts and treatment options. Eur J Med Res. 2021 Aug 4
- Mears SC, Kates SL. A Guide to Improving the Care of Patients with Fragility Fractures, Edition 2. Geriatr Orthop Surg Rehabil. 2015 Jun;6
- Beaupre LA, Khong H, Smith C, Kang S, Evens L, Jaiswal PK, Powell JN. The impact of time to surgery after hip fracture on mortality at 30- and 90-days: Does a single benchmark apply to all? Injury. 2019

Jāpielāgo fiksācija pie kaulu deformācijas

- Pie osteoporozes īpaši bisfosfosfonātu lietošanas novēro augšstilba kaula izliekšanos, un antekurvācijas deformāciju
- Ja tas netiek pamanīts un ņemts vērā, tad intraoperatīvi tas var novest pie komplikācijām:
  - Neprecīza repozīcija
  - Jatrogēns lūzums
  - Kaula perforācija ar metāla konstrukcijām.

- Mismatch of anatomically pre-shaped locking plate on Asian femurs could lead to malalignment in the minimally invasive plating of distal femoral fractures: a cadaveric study. Arch Orthop Trauma Surg. 2012 Jan
- Low-energy diaphyseal femoral fractures associated with bisphosphonate use and severe curved femur: a case series. J Bone Miner Metab. 2012 Sep

15°

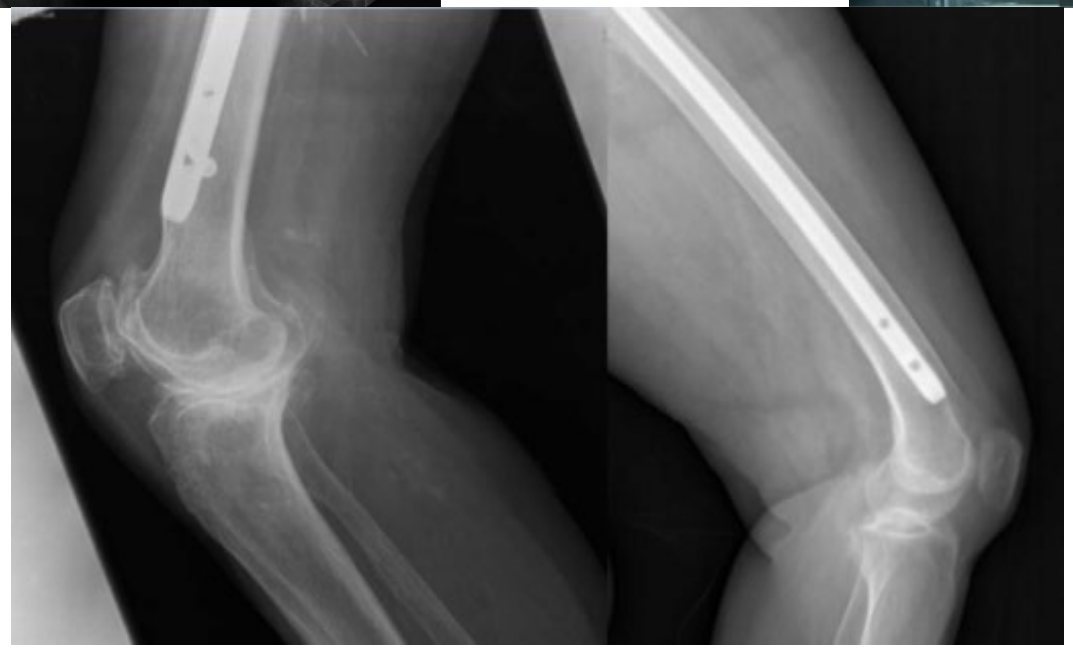

Izvēlētai fiksācijas metodei jāiztur pacienta pilna lūzuma zonas slogošana - «one shot surgery» princips

Izvēlētai fiksācijas metodei jāiztur pacienta pilna lūzuma zonas slogošana - «one shot surgery» princips

- Elabd MA, Mahmoud AN, Elzaher EH, Kamel ME. Early ambulation and good outcomes after using combined nail plate construct for fixation of distal femoral fractures: a retrospective series of 14 cases. Int J Burns Trauma. 2023 Aug 15
- Kontakis MG, Giannoudis PV. Nail plate combination in fractures of the distal femur in the elderly: A new paradigm for optimum fixation and early mobilization? Injury. 2023 Feb;54
- Tripathy SK, Mishra NP, Varghese P, Panigrahi S, Purudappa PP, Goel A, Sen RK. Dual-Plating in Distal Femur Fracture: A Systematic Review and Limited Meta-analysis. Indian J Orthop. 2021 Aug 23

Izvēlētai fiksācijas metodei jāiztur pacienta pilna lūzuma zonas slogošana - «one shot surgery» princips

Izvēlētai fiksācijas metodei jāiztur pacienta pilna lūzuma zonas slogošana - «one shot surgery» princips

- Koval KJ, Sala DA, Kummer FJ, et al. Postoperative weight-bearing after a fracture of the femoral neck or an intertrochanteric fracture. J Bone Joint Surg Am. 1998 Mar
- Joslin CC, Eastaugh-Waring SJ, Hardy JR, et al. Weight bearing after tibial fracture as a guide to healing. Clin Biomech (Bristol, Avon). 2008 Mar

Atkārtotu lūzumu risku mazināšana

- **D3 + kalcijs**
- **Specifiskie osteoporozes ārstēšanas medikamenti**
- **Multivitamīnu komplekss**
- **Diēta ar augstu proteīna saturu**
- **Līdzsvara un rezistences vingrinājumi**
- **Kritienu risku mazināšana, piederīgo izglītošana.**

Richard E Buckley, Christopher G Moran, Theerachai Apivatthakakul AO Principles of Fracture Management—Third Edition, page 465-466.

D vitamīna un kalcija deficīts

- 80-95% pacientiem ar osteoporotiskiem lūzumiem ir D vitamīna deficīts (<50nmol/L)
- D vitamīna daudzums 2000 SV – 10000 SV
- Kalciju vēlams uzņemt ar uzturu, bet var papildus ar uztura bagātinātājiem.

- Han J, Cho Y, Jee S, Jo S. Vitamin D Levels in Patients with Low-energy Hip Fractures. Hip Pelvis. 2020 Dec
- Bischoff-Ferrari HA, Can U, Staehelin HB et al. Severe vitamin D deficiency in Swiss hip fracture patients.
- Gallacher SJ, McQuillian C, Harkness M, Finlay F, Gallagher AP, Dixon T. Prevalence of vitamin D inadequacy in Scottish adults with non-vertebral fragility fractures
- Richard E Buckley, Christopher G Moran, Theerachai Apivatthakakul AO Principles of Fracture Management—Third Edition, page 465.

Specifiskie osteoporozes ārstēšanas medikamenti

Vai varam uzsākt antirezorbtīvo medikamentu lietošanu, ja varam, tad kad un ja tie uzsākti vai turpināt?

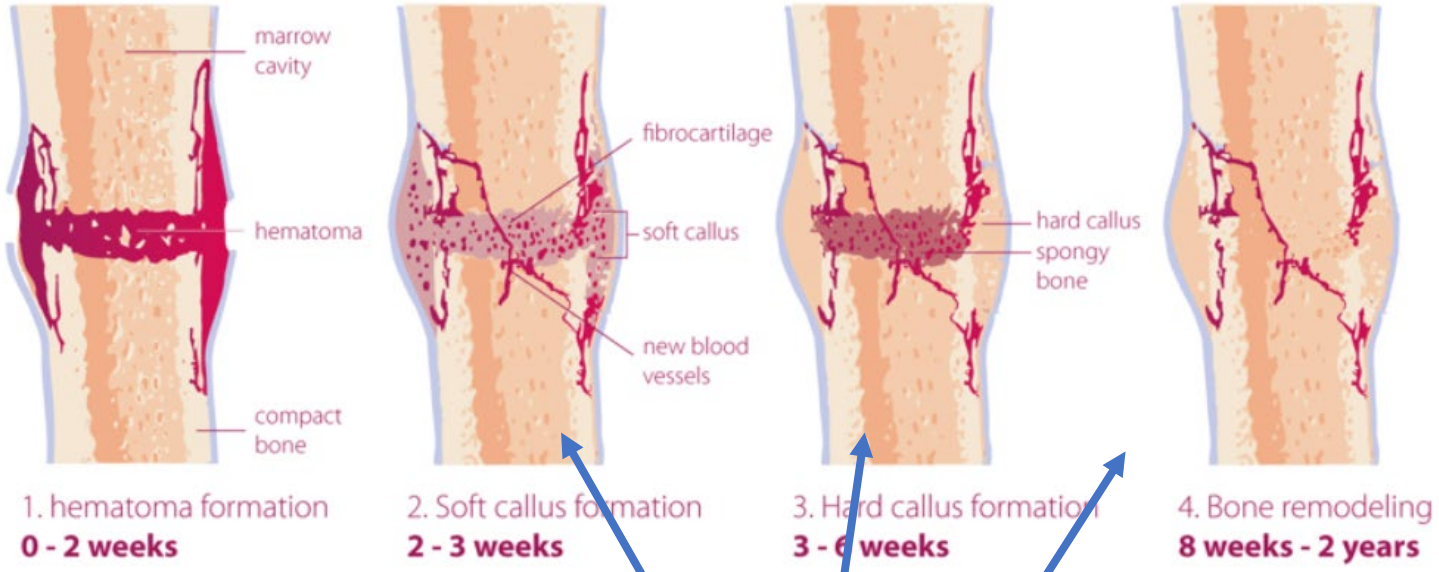

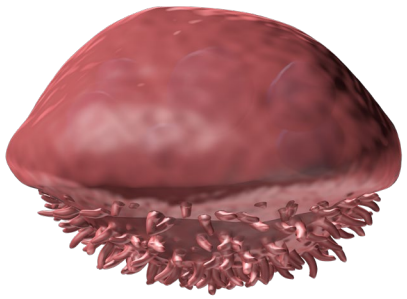

Osteoklasti

Marsell R, Einhorn TA. The biology of fracture healing. Injury. 2011 Jun

Table 2. Summary of published studies with bisphosphonates treatment in osteoporotic fracture healing (study protocol and methodology)

References	Year	Study design	Fracture type	Fracture treatment	n (case/control)	Treatment drug	Drug initiation	Treatment period	Combined treatment	Evaluation methodology	
										Fracture healing	Functional recovery
van der Poest Clement et al. [10]	2000	PRCT	Distal forearm fracture	Conservative treatment	16/17	Oral alendronate 10 mg/day vs. placebo	After 2-4 weeks	12 months	Calcium	Plain radiographs	Lidstrom score (1 year)
Rozental et al. [11]	2009	Retrospective	DRF	Conservative treatment or operation	43/153 (current users vs. nothing)	Oral alendronate or risedronate vs. nothing				Plain radiographs	
Gong et al. [13]	2012	PRCT	DRF	ORIF	24/26 (different medication timing)	Oral alendronate 70 mg/week	After 2 weeks vs. after 3 months			Plain radiographs (2/6/10/16/24 weeks)	DASH score, Wrist ROM, Grip strength (24 weeks)
Uchiyama et al. [14]	2013	Prospective study	DRF	ORIF	39/32 (different medication timing)	Oral alendronate 35 mg/week	Within few days vs. after 4 months			Plain radiographs (1/2/3/4/5/6 months)	Quick DASH score, Wrist ROM, Grip strength, Fracture tenderness
Shoji et al. [12]	2018	Prospective study	DRF	Conservative treatment	12/23 (current users vs. nothing)	Oral alendronate, ibandronate, or risedronate vs. nothing				Plain radiographs (6/9/12 weeks/ 1 year)	DASH score, PRWE score, Wrist ROM, Grip and pinch strength (1 year)
Duckworth et al. [15]	2019	PRCT	DRF	Conservative treatment or operation	215/206	Oral alendronate 70 mg/week	Within 2 weeks	24 weeks		Plain radiographs (2/4/6/8 weeks)	DASH score, Wrist ROM, Grip strength, Fracture site pain (26 weeks)
Colón-Emeric et al. [18]	2011	PRCT	Hip fracture	Operation	1054/1057	IV zoledronate 5 mg/year	Within 90 days	3 years	Calcium +Vit D	Plain radiographs	
Kim et al. [19]	2012	PRCT	Femur intertrochanteric fracture	Operation	26/26/25 (different medication timing)	Oral risedronate 35 mg/week	After 1 week vs. after 1 month vs. after 3 months	1 year	Calcium +Vit D	Plain radiographs (4/8/12/16/20/24 weeks/1 year)	Koval score (1 year)
Lim et al. [20]	2019	Retrospective	Femur intertrochanteric fracture	Internal fixation	29/101 (history of bisphosphonates vs. nothing)	Oral alendronate, oral or IV ibandronate, oral risedronate, or IV zoledronate vs. nothing				Plain radiographs (6 weeks/3/6 months/ 1 year)	Koval score (1 year)
Ha et al. [21]	2016	Prospective study	Spine fracture	Conservative treatment	66/39 (current users vs. nothing)	Oral alendronate 70 mg/week or risedronate 35 mg/week				Plain radiographs	Pain, Oswestry disability index (3 months)

PRCT, prospective randomized controlled trial; DRF, distal radius fracture; DASH, disabilities of the arm, shoulder and hand; ROM, range of motion; PRWE, patient rated wrist evaluation; IV, intravenous; Vit, vitamin.

Table 3. Summary of published studies with bisphosphonates treatment in osteopor

Author	Year	Fracture healing	
		Union rate	Time to union
van der Poest Clement et al. [10]	2000	100% vs. 100% (1 delayed union)	
Rozental et al. [11]	2009	100% (1 delayed union) vs. 100%	55 vs. 49 days (P=0.03)
Gong et al. [13]	2012	83% vs. 77% (6 weeks) (P=0.814) 100% vs. 100% (10 weeks)	6.7 vs. 6.8 weeks (P=0.650)
Uchiyama et al. [14]	2013	100% vs. 100% (6 months)	3.5 vs. 3.1 months (P=0.068)
Shoji et al. [12]	2018	16.7% vs. 17.4% (6 weeks) 25.0% vs. 39.1% (9 weeks) 41.7% vs. 56.5% (12 weeks) 100% vs. 100% (1 year)	
Duckworth et al. [15]	2019	23.8% vs. 27.8% (4 weeks) (P=0.31) 44.6% vs. 44.2% (6 weeks) (P=0.88) 61.7% vs. 56.3% (8 weeks) (P=0.19) 100% vs. 100% (24 weeks)	
Colón-Emeric et al. [18]	2011	Incidence of delayed healing: 3.2% vs. 2.7 (P=0.61)	
Kim et al. [19]	2012	12.5% vs. 13.0% vs. 25.0% (4 weeks) 45.8% vs. 34.8% vs. 41.7% (8 weeks) 83.3% vs. 65.2% vs. 62.5% (12 weeks) 91.7% vs. 73.9% vs. 79.2% (16 weeks) 100% vs. 91.3% vs. 100% (20 weeks) 100% vs. 100% vs. 100% (24 weeks)	10.7 vs. 12.9 vs. 12.3 weeks (P=0.420)
Lim et al. [20]	2019	72.4% vs. 91.1% (3 months) (P=0.028) 93.1% vs. 96.0% (1 year) (P=0.310)	
Ha et al. [21]	2016	Vertebral height loss: 36.1% vs. 38.7% (P>0.05) Kyphotic angle (degrees): 16.8 vs. 20.2 (P>0.05)	

Līdzsvara un rezistences vingrinājumi

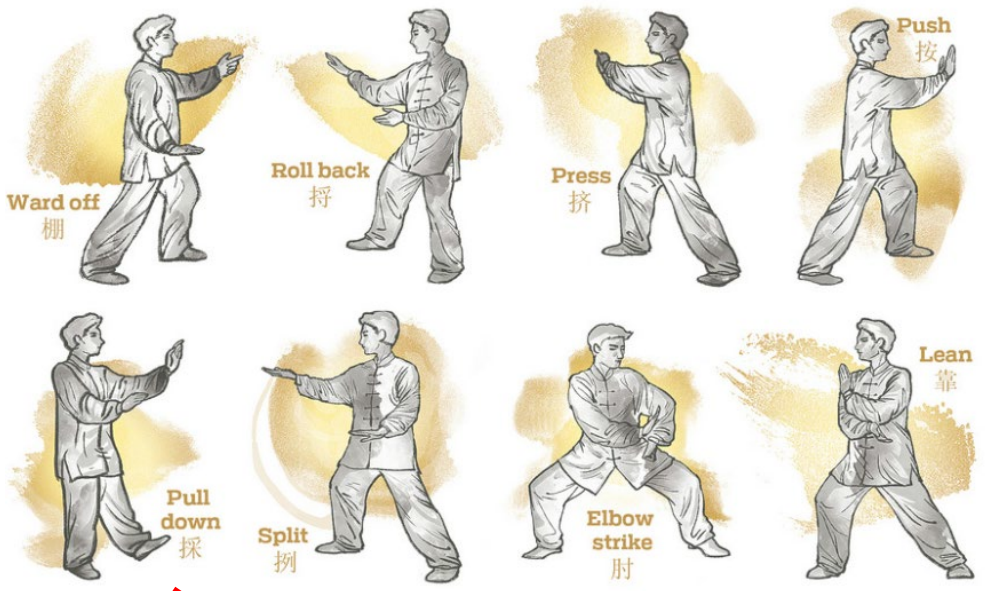

Kritienu risku mazināšana, piederīgo izglītošana.

Take-home message

- Osteoporoze un osteoporotiskie lūzumi ir pieaugoša problēma.
- Svarīgi identificēt pirmo osteoporotisko lūzumu - pacientu izmeklēt un uzsākt mērķtiecīgu ārstēšanu.
- Pacientiem ar osteoporotiskiem lūzumiem funkcionalitāte ir zemāka un mirstība augstāka.
- Osteoporotisku lūzumu ārstēšana ir sarežģīta ar paaugstinātiem komplikāciju riskiem.
- Antirezorbtīvo medikamentu lietošana nozīmīgi neietekmē traumatiksu lūzumu konsolidēšanos.